



Taxonomy and systematics

Helminths of the common opossum *Didelphis marsupialis* (Didelphimorphia: Didelphidae), with a checklist of helminths parasitizing marsupials from Peru

Helminths of the common opossum Didelphis marsupialis (Didelphimorphia: Didelphidae), con una lista de los helmintos de marsupiales de Perú

Jhon D. Chero^{a,*}, Gloria Sáez^a, Carlos Mendoza-Vidaurre^b, José Iannacone^c, Celso L. Cruces^a

^a Laboratorio de Parasitología, Facultad de Ciencias Naturales y Matemática, Universidad Nacional Federico Villarreal, Jr. Río Chepén 290, El Agustino, 15007 Lima, Peru

^b Universidad Alas Peruanas, Jr. Martínez Copagnon Núm. 1056, 22202 Tarapoto, San Martín, Peru

^c Laboratorio de Parasitología, Facultad de Ciencias Biológicas, Universidad Ricardo Palma, Santiago de Surco, 15039 Lima, Peru

Received 9 June 2016; accepted 27 March 2017

Available online 19 August 2017

Abstract

Between May and November 2015, 8 specimens of *Didelphis marsupialis* Linnaeus, 1758 (Didelphimorphia: Didelphidae) collected in San Martín, Peru were examined for the presence of helminths. A total of 582 helminths representing 11 taxa were identified (2 digeneans and 9 nematodes). Five new host records and 4 species of nematodes [*Gongylonemoides marsupialis* (Vaz & Pereira, 1934) Freitas & Lent, 1937, *Trichuris didelphis* Babero, 1960, *Viannaia hamata* Travassos, 1914 and *Viannaia viannaia* Travassos, 1914] are added to the composition of the helminth fauna of the marsupials in this country. Further, a checklist of all available published accounts of helminth parasites reported from Peru is provided. To date, a total of 38 helminth parasites have been recorded. Digeneans have the highest species richness in number and percentage (n = 19, 50%), followed by nematodes (n = 17, 45%) and acanthocephalans (n = 2, 5%). The parasites with the highest number of records were the digeneans *Plagiorchis didelphidis* (Parona, 1896) Stossich, 1904 (n = 4) and *Rhopalias coronatus* Kifune & Uyema, 1982 (n = 4) and the nematode *Aspidodera* sp. (n = 4). Additional sampling in this country will probably increase the richness of the helminthological inventory of this group of mammals.

© 2017 Universidad Nacional Autónoma de México, Instituto de Biología. This is an open access article under the CC BY-NC-ND license (<http://creativecommons.org/licenses/by-nc-nd/4.0/>).

Keywords: *Plagiorchis didelphidis*; *Rhopalias coronatus*; Mammals; *Philander opossum*; Neotropical; *Metachirus nudicaudatus*

Resumen

Entre mayo y noviembre del 2015, 8 ejemplares de *Didelphis marsupialis* Linnaeus, 1758 (Didelphimorphia: Didelphidae) recolectados en San Martín, Perú, fueron examinados en busca de helmintos. Un total de 582 helmintos representando 11 taxones fueron identificados (2 digéneos y 9 nemátodos). Cinco registros nuevos y 4 especies de nemátodos [*Gongylonemoides marsupialis* (Vaz y Pereira, 1934) Freitas y Lent, 1937, *Trichuris didelphis* Babero, 1960, *Viannaia hamata* Travassos, 1914 y *Viannaia viannaia* Travassos, 1914] se agregan a la composición de la fauna de helmintos de marsupiales de Perú. Además, se proporciona una lista de todos los registros publicados de este grupo de parásitos para marsupiales en dicho país. Hasta la fecha, se ha registrado un total de 38 helmintos; los digéneos tienen la mayor riqueza de especies en número

* Corresponding author.

E-mail address: crithian-5645@hotmail.com (J.D. Chero).

Peer Review under the responsibility of Universidad Nacional Autónoma de México.

y porcentaje (n = 19, 50%), seguido por los nemátodos (n = 17, 45%) y acantocéfalos (n = 2, 5%). Los parásitos con mayor número de registros fueron los digéneos *Plagiorchis didelphidis* (Parona, 1896) Stossich, 1904 (n = 4) y *Rhopalias coronatus* Kifune y Uyema, 1982 (n = 4) y el nemátodo *Aspidodera* sp. (n = 4). Nuevos muestreos en este país probablemente aumentarán la riqueza del inventario helmintológico de este grupo de mamíferos.

© 2017 Universidad Nacional Autónoma de México, Instituto de Biología. Este es un artículo Open Access bajo la licencia CC BY-NC-ND (<http://creativecommons.org/licenses/by-nc-nd/4.0/>).

Palabras clave: *Plagiorchis didelphidis*; *Rhopalias coronatus*; Mamíferos; *Philander opossum*; Neotropical; *Metachirus nudicaudatus*

Introduction

With 508 species of native mammals, Peru is the third most diverse country in the New World, after Brazil and Mexico, and the fifth most diverse for mammals in the world (Pacheco, Cadenillas, Salas, Tello, & Zeballos, 2009). In Peru, the order Didelphimorphia is represented by the family Didelphidae with 40 species in 13 recognized genera (Pacheco et al., 2009). However, despite this great diversity, the information on its helminth parasites is still very scarce (Tantaleán, Díaz, Sánchez, & Portocarrero, 2010).

The common opossum, *Didelphis marsupialis* Linnaeus, 1758, is a marsupial species in the family Didelphidae, living in rainforest and subtropical forest, secondary forest, and near human settlements. This species is widely distributed from Mexico, south to Peru, Bolivia, Paraguay and northeastern Argentina, including Trinidad and the Lesser Antilles (Aponte, 2013; Emmons & Feer, 1997; Rueda, Ramírez, & Osorio, 2013). It is listed as presenting Least Concern status by the International Union for Conservation of Nature and Natural Resources (IUCN Red List). Information about parasite diversity of this species in different countries along its geographical distribution is scarce (Acosta-Virgen, López-Caballero, García-Prieto, & Mata-López, 2015; Fernandes, Justo, & Cárdenas, 2015; García-Prieto, Falcón-Ordaz, & Guzmán-Cornejo, 2012; Jiménez, Catzefflis, & Gardner, 2011; Rodríguez-Ortiz, García-Prieto, & Pérez-Ponce de León, 2004). Although there are some reports of digeneans (Kifune & Uyema, 1982; Miyazaki, Kifune, Habe, & Uyema, 1978; Tantaleán, Sarmiento, & Huiza, 1992), nematodes (Arrojo, 2002; Sarmiento, Tantaleán, & Huiza, 1999; Tantaleán et al., 2010) and acanthocephalans (Tantaleán, Sánchez, Gómez, & Huiza, 2005) from *D. marsupialis* in Peru, the knowledge of the helminth richness associated with this host species is still incomplete due to the wide distribution of this host in Peru.

In the present study, we report new records of helminth species parasitizing *D. marsupialis* in Peru. In addition, a checklist of helminth parasites of Peruvian marsupials is presented.

Materials and methods

Between May and November 2015, 8 specimens of *D. marsupialis* (Didelphidae) were found dead in the jungle of San Martín, Peru (Fig. 1). The specimens were collected and transferred to the laboratory of Clinical Analysis Morales

Lab. for the respective necropsy. During the necropsy of hosts, trematodes and nematodes were extracted from the gastrointestinal tract, placed in Petri dishes with tap water, fixed in 4% hot formaldehyde and preserved in 70% ethanol. For morphological study, trematodes were stained with Semichon's carmine, dehydrated in successive series of ethanol (up to absolute ethanol), cleared in Eugenol and mounted in Canada balsam. Nematodes were cleared in Amman's lactophenol and temporarily mounted for morphological study (Lamothe-Argumedo, 1997). The parasites were analyzed and measured using a Leica-DM500 microscope with LEICA-ICC50 HD camera and Software LAS (Leica Application Suite), EZ versión 1.80, 2009, Switzerland. Measurements are in millimeters (mm). The taxonomic determination of the parasites was in accordance with the diagnosis proposed by Gibson, Jones, and Bray (2002) and Haverkost and Gardner (2008) for trematodes, and Chagas-Moutinho, Oliveira-Menezes, Cárdenas, and Lanfredi (2007), Lent and Freitas (1937a,b), Santos, Lent, and Gomes (1990), Travassos (1922), Vicente (1966), and Vicente, Rodrigues, Gomes, and Pinto (1997) for nematodes. The terms prevalence and mean intensity were used according to Bush, Lafferty, Lotz, and Shostak (1997).

Vouchers of all helminth species were deposited in the Helminthological and Minor Invertebrates Collection of the Museum of Natural History at the San Marcos University (MUSM), Peru.

Furthermore, a checklist was compiled based on the new and previous reports of helminths parasites of marsupials from Peru. Undergraduate theses and scientific meetings do not constitute formal publications, and thus were not considered. Records published until April 2016 were included. The checklist consists of 2 sections: the first part is the list of helminth parasites of marsupials, indicating host, site of infection, locality and reference. The taxonomy of helminths follows Amin (2013) for Acanthocephala, Anderson, Chabaud, and Willmott (2009) for Nematoda, and Gibson et al. (2002) for Trematoda. The second part includes the list of hosts and their respective parasites. Marsupial species are in alphabetical order. The updated name of marsupials follows Pacheco et al. (2009).

In this work, all applicable institutional, national and international guidelines for the care and use of wild animals were followed. Furthermore, all individuals of the host *D. marsupialis* were found dead and are not considered as Critically Endangered by IUCN.

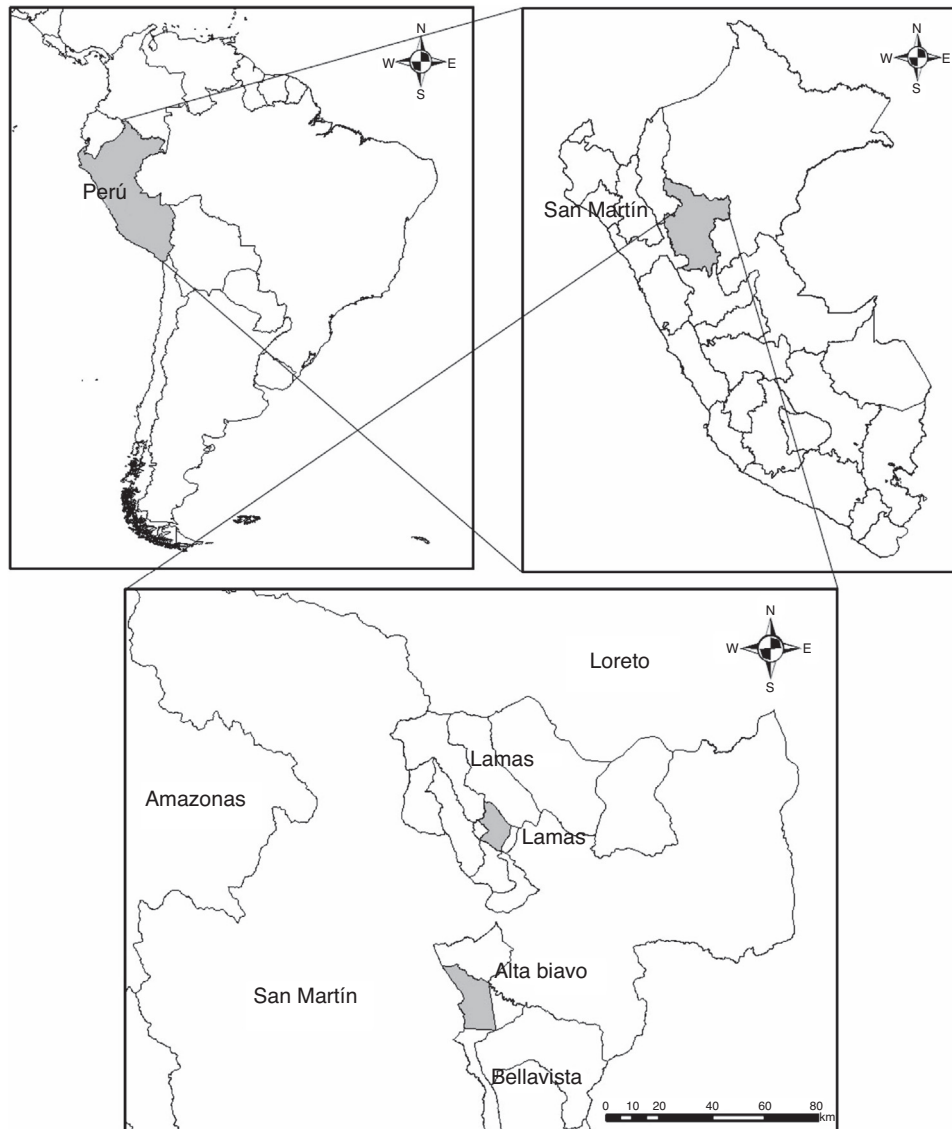


Figure 1. Study area in the jungle of San Martín, Peru.

Results

A total of 582 endoparasites were collected in the study specimens and the total prevalence was 100%. Morphological analyses of parasites permitted the identification of 11 taxa (2 digeneans and 9 nematodes) belonging to 9 genera and 8 families.

Phylum Platyhelminthes Gegenbaur, 1959

Class Trematoda Rudolphi, 1808

Family Plagiorchiidae Ward, 1917

Plagiorchis didelphidis (Parona, 1869) Stossich, 1904

Description: based on 5 adult specimens. Body 4.754–6.455 (5.452) long, maximum width 1.383–1.724 (1.583). Tegument covered with numerous small spines. Oral sucker subterminal,

0.420–0.564 (0.518) long by 0.537–0.708 (0.649) wide. Pharynx 0.239–0.333 (0.303) long by 0.260–0.393 (0.348) wide. Acetabulum 0.676–0.956 (0.837) long by 0.708–1.026 (0.872) wide. Anterior testis 0.421–0.611 (0.513) long by 0.475–0.703 (0.554) wide. Posterior testis 0.444–0.640 (0.528) long by 0.455–0.655 (0.535). Ovary 0.268–0.328 (0.289) long by 0.213–0.337 (0.289) wide. Eggs numerous, 0.042–0.046 long by 0.019–0.021 wide.

Taxonomic summary

Infection site: small intestine.

Locality: Bella Vista, San Martín, Peru (7°15' S, 76°28' W).

Specimens deposited: MUSM 3400.

Prevalence: 25% (2 infected marsupials of 8).

Mean intensity: 8.

Mean abundance: 2.

Remarks

Species of *Plagiorchis* Luehe, 1899 are intestinal trematodes of amphibians, reptiles, birds and mammals (Rodrigues, 1994). In Peru, 2 species are currently known: *P. didelphidis* from *D. marsupialis*, *Didelphis albiventris* Lund, 1840, *Metachirus nudicaudatus* (É. Geoffroy, 1803) and *Philander opossum* (Linnaeus, 1758) and *Plagiorchis* sp. from *Leucophaeus pipixcan* (Wagler, 1831) (Tantaleán et al., 1992). This species is also described for Brazil and Paraguay (Fernandes et al., 2015).

Family Rhopaliasidae (Looss, 1899) Yamaguti, 1958

Rhopalias caballeroi Kifune & Uyema, 1982

Description: based on 5 adult specimens. Body 3.489–4.090 (3.79) long, maximum width 0.820–1.074 (0.95). Oral sucker 0.058–0.254 (0.130) long by 0.070–0.283 (0.130) wide. Pharynx 0.053–0.223 (0.121) long by 0.030–0.149 (0.077) wide. Esophagus 0.097 long. Acetabulum 0.319–0.370 (0.345) long by 0.289–0.341 (0.315) wide. Cirrus sac 0.230–0.938 (0.512) long. Anterior testis 0.488–0.541 (0.515) long by 0.515–0.547 (0.531) wide. Posterior testis 0.582–0.924 (0.750) long by 0.438–0.448 (0.440) wide. Ovary 0.120–0.229 (0.169) long by 0.233–0.238 (0.236) wide. Eggs 0.093–0.099 (0.096) long by 0.057–0.060 (0.058) wide.

Taxonomic summary

Infection site: small intestine and tongue.

Locality: Bella Vista, San Martín, Peru (7°15' S, 76°28' W); Lamas, San Martín, Peru (6°25' S, 76°30' W).

Specimens deposited: MUSM 3401.

Prevalence: 50% (4 infected marsupials of 8).

Mean intensity: 2.5.

Mean abundance: 0.625.

Remarks

Species of *Rhopalias* (Rudolphi, 1819) are parasites of the small intestines of marsupials from the Nearctic and Neotropical regions (Haverkost & Gardner, 2008; Fernandes et al., 2015). Five species, namely *R. baculifer* Braun, 1900, *R. caballeroi*, *R. coronatus* Kifune & Uyema, 1982, *R. horridus* (Diesing, 1850) and *Rhopalias* sp. have been reported in Peru (Miyazaki et al., 1978; Morales, Sarmiento, Sánchez, Floríndez, & Lamas, 2005; Tantaleán & Chávez, 2004; Tantaleán et al., 1992). According to Haverkost and Gardner (2008), *R. caballeroi* is distinguished by the absence of oral and flanking spines, and because it has between 4 and 11 spines visible within tentacle sacs. This species has also been reported for Argentina, Bolivia, Brazil, Colombia, Mexico, and Paraguay (Acosta-Virgen et al., 2015; Fernandes et al., 2015).

Rhopalias coronatus (Rudolphi, 1819) Stiles & Hassall, 1898

Description: based on 5 adult specimens. Body 2.452–9.352 (4.436) long, maximum width 0.212–1.581 (0.733). Oral sucker 0.120–0.344 (0.183) long by 0.088–0.325 (0.178) wide. Pharynx 0.111–0.421 (0.201) long by 0.042–0.244 (0.121) wide. Acetabulum 0.149–0.821 (0.376) long by 0.156–0.800 (0.352) wide. Cirrus sac 0.562–2.198 (0.966)

long. Anterior testis 0.158–0.624 (0.336) long by 0.102–0.263 (0.160) wide. Posterior testis 0.249–0.900 (0.500) long by 0.075–0.276 (0.149) wide. Ovary 0.070–0.345 (0.164) long by 0.089–0.351 (0.177) wide. Eggs 0.069–0.105 (0.092) long by 0.031–0.068 (0.048) wide.

Taxonomic summary

Infection site: small intestine and tongue.

Locality: Lamas, San Martín, Peru (6°25' S, 76°30' W).

Specimens deposited: MUSM 3402.

Prevalence: 25% (2 infected marsupials of 8).

Mean intensity: 11.

Mean abundance: 2.75.

Remarks

This species is a common intestinal parasite of marsupials from North, Central and South America (Fernandes et al., 2015; Haverkost & Gardner, 2008; Rivillas, Caro, Carvajal, & Vélez, 2004). According to Haverkost and Gardner (2008), *R. coronatus* is distinguished by the presence of flanking and oral spines, between 3 and 11 spines visible within tentacle sacs, which extend far beyond the posterior margin of the pharynx. In Peru, *R. coronatus* has been registered in four marsupial hosts. This species has also been recorded from Argentina, Bolivia, Brazil, Costa Rica, Ecuador, Mexico, Paraguay, and Venezuela (Acosta-Virgen et al., 2015; Fernandes et al., 2015; Rodríguez-Ortiz et al., 2004).

Phylum Nematoda Rudolphi, 1808

Family Aspidoderidae Skrjabin & Schikhobalova, 1947

Aspidodera raillieti Travassos, 1913

Description: based on 12 adult specimens (6 male and 6 female). **Male:** Body 5.78–7.91 (7.10) long by 0.22–0.32 (0.28) wide. Cephalic expansion 0.12–0.16 (0.14) long. Esophagus 0.75–0.89 (0.84) long, bulb 0.22–0.27 (0.25) long by 0.17–0.21 (0.19) wide. Excretory pore at 0.60–0.76 (0.68) from anterior end. Spicules 0.84–1.07 (0.94) long. Gubernaculum 0.20–0.23 (0.21) long. Cloaca at 0.41–0.51 (0.47) from posterior end. **Female:** Body 7.60–8.67 (8.05) long by 0.41–0.49 (0.45) wide. Cephalic expansion 0.15–0.18 (0.16) long. Esophagus 0.85–1.06 (0.98) long, bulb 0.25–0.30 (0.27) long by 0.22–0.25 (0.24) wide. Excretory pore at 0.61–0.73 (0.68) from anterior end. Vulva located at the middle of the body 2.93–3.09 (3.02) from the anterior end. The anal opening at 1.03–1.13 (1.08) from the posterior end. Eggs 0.06–0.07 (0.068) long by 0.04–0.05 (0.043) wide.

Taxonomic summary

Infection site: small intestine.

Locality: Bella Vista, San Martín, Peru (7°15' S, 76°28' W); Lamas, San Martín, Peru (6°25' S, 76°30' W).

Specimens deposited: MUSM 3251.

Prevalence: 63% (5 infected marsupials of 8).

Mean intensity: 18.2.

Mean abundance: 11.37.

Remarks

Nematodes of the family Aspidoderidae are widely distributed in the Americas, in countries such as Brazil, Mexico, Panama, Paraguay, Trinidad, Argentina, USA, Peru, Bolivia, Guatemala, Venezuela, and Suriname (Chagas-Moutinho et al., 2007). These nematodes are parasites of mammals of the orders Edentata, Marsupialia, and Rodentia (Chagas-Moutinho et al., 2007; Jiménez-Ruiz, Gardner, & Varela-Stokes, 2006; Santos et al., 1990). Santos et al. (1990) reviewed the genus and established some characters to identify these nematodes to the level of species, which include the cephalic cordons, the shape and length of the spicules, the shape of the spinneret, and the number of caudal papillae (Gomes, da Cruz, Vicente, & Pinto, 2003; Jiménez-Ruiz et al., 2006). *Aspidodera raillieti* was described by Travassos (1913) on the basis of specimens collected in the caecum from the Brazilian Common Opossum *Didelphis aurita* (Wied-Neuwi, 1826) from Brazil. The taxonomic characters were performed by Chagas-Moutinho et al. (2007) and Santos et al. (1990). According to Sarmiento et al. (1999) specimens of *Aspidodera harwoodi* Chandler, 1932 have been recorded from *D. marsupialis* in Peru. However, Santos et al. (1990) considered *A. harwoodi* synonymous of *A. raillieti*. Other hosts of *A. raillieti* include *Caluromys lanatus* (Olfers, 1818); *Didelphis virginiana* Allen, 1900; *D. albiventris*; *D. aurita*; *Chironectes minimus* (Zimmermann, 1780); *Chirotopes satanas* (Hoffmannsegg, 1807); *P. opossum* and *Nectomys squamipes* (Brants, 1827) and *Tolypeutes tricinctus* (Linnaeus, 1758); *T. apereoides* in Brazil and *D. virginiana* in Mexico (Acosta-Virgen et al., 2015; Pinto, Knoff, Gomes, & Noronha, 2011; Vicente et al., 1997). This species is also listed in Brazil and Mexico, in *D. marsupialis* (Chagas-Moutinho et al., 2007; Jiménez et al., 2011).

Family Kathlaniidae Travassos, 1918

Cruzia tentaculata (Rudolphi, 1819) Travassos, 1917

Description: based on 10 adult specimens (5 male and 5 female). **Male:** Body 11.78–12.91 (12.30) long by 0.54–0.71 (0.68) wide. Esophagus 2.75–2.89 (2.84) long, bulb 0.29–0.30 (0.25) long by 0.27–0.30 (0.28) wide. Excretory pore at 1.18–1.30 (1.20) from anterior end. Spicules 0.80–0.93 (0.89) long. Gubernaculum 0.16–0.20 (0.19) long. Cloaca at 0.15–0.20 (0.18) from posterior end. **Female:** Body 11.60–12.67 (10.05) long by 0.50–0.58 (0.51) wide. Oral capsule 0.18–0.26 (0.22) long. Esophagus 1.85–2.06 (1.98) long, bulb 0.25–0.28 (0.27) long by 0.26–0.29 (0.27) wide. Excretory pore at 1.18–1.30 (1.23) from anterior end. Vulva located at the middle of the body 5.24–5.34 (5.26) from the anterior end. The anal opening at 0.70–1.09 (0.98) from the posterior end. Eggs 0.1–0.12 (0.11) long by 0.04–0.05 (0.04) wide.

Taxonomic summary

Infection site: small intestine.

Locality: Bella Vista, San Martín, Peru (7°15' S, 76°28' W); Lamas, San Martín, Peru (6°25' S, 76°30' W).

Specimens deposited: MUSM 3253.

Prevalence: 63% (5 infected marsupials of 8).

Mean intensity: 15.2.

Mean abundance: 9.5.

Remarks

Species of *Cruzia* are parasites of the large intestine of marsupials, reptiles, amphibians, and mammals (Adnet, Anjos, Menezes-Oliveira, & Lanfredi, 2009). The specimens collected from the small intestine of *D. marsupialis* belonging to the genus *Cruzia* Travassos, 1917 by having a mouth with three well-developed triangular lips, pharynx with three longitudinal rows of hooks and three structures truncated like tooth at the base, esophagus with well-developed bulb and with anterior blind intestine (Vicente et al., 1997). Morphometric characteristics of the specimens studied in the present paper fit with the aforementioned by Travassos (1917) and Vicente et al. (1997) for *Cruzia tentaculata* (Rudolphi, 1819) Travassos, 1917. *Cruzia tentaculata* is a common parasite of marsupials in South and Central America (Gomes et al., 2003; Pinto et al., 2011). In Peru, *C. tentaculata* has been found parasitizing the intestine of *D. marsupialis* and *M. nudicaudatus* (Geoffroy, 1803) from Cajamarca and Iquitos, respectively (Sarmiento et al., 1999; Tantaleán et al., 2010).

Family Gongylonematidae Sobolev, 1949

Gongylonemoides marsupialis (Vaz & Pereira, 1934) Freitas & Lent, 1937

Description: based on 10 adult specimens (6 male and 4 female). **Male:** Body 20.64–22.32 (21.10) long by 0.22–0.27 (0.24) wide. Muscular and glandular esophagus 0.50–0.64 (0.52) and 3.60–3.7 (3.65) long, respectively. Excretory pore at 0.60–0.68 (0.66) from anterior end. Right and left spicules 0.28–0.30 (0.29) and 0.154–0.180 (0.16) long, respectively. Cloaca at 0.205–0.208 (0.207) from posterior end. **Female:** Body 45.60–46.67 (46.05) long by 0.30–0.32 (0.31) wide. Muscular and glandular esophagus 0.60–0.71 (0.68) and 6.48–6.72 (6.65) long, respectively. Excretory pore at 0.65–0.72 (0.66) from anterior end. Vulva located at the middle of the body 5.60–6.09 (5.80) from the posterior end. The anal opening at 0.237–0.263 (0.240) from the posterior end. Eggs 0.04–0.05 (0.04) long by 0.01–0.02 (0.01) wide.

Taxonomic summary

Infection site: trachea.

Locality: Lamas, San Martín, Peru (6°25' S, 76°30' W).

Specimens deposited: MUSM 3254.

Prevalence: 25% (2 infected marsupials of 8).

Mean intensity: 15.

Mean abundance: 3.75.

Remarks

The species was described as *Gongylonema marsupialis* by Vaz and Pereira (1934) based on a female specimen collected from *D. aurita* from Brazil. Freitas and Lent (1937) created the genus *Gongylonemoides* to include this species, considering the absence of the gubernaculum, the most outstanding character. The specimens studied herein were closer to these referred by

Freitas and Lent (1937). *Gongylonemoides marsupialis* has been registered in *D. aurita*, *D. marsupialis*, and *M. opossum* from Brazil (Gomes et al., 2003; Vicente et al., 1997). This paper constitutes the first register of this nematode species in Peru.

Family Physalopterae Leiper, 1908

Physaloptera mirandai Lent & Freitas, 1937

Description: based on 10 adult specimens (5 male and 5 female). *Male:* Body 29.75–37.55 (32.05) long by 0.45–0.99 (0.77) wide. Muscular and glandular esophagus 0.64–0.89 (0.78) and 4.33–7.08 (5.84) long, respectively. Excretory pore at 1.01–1.21 (1.13) from anterior end. Spicules, 0.46–0.62 (0.55) long. Cloacal aperture at 1.47–2.04 (1.71) from posterior end. *Female:* Body 30.87–46.31 (37.80) long by 0.64–1.03 (0.84) wide. Muscular and glandular esophagus 0.67–0.94 (0.76) and 7.49–8.40 (7.74) long, respectively. Excretory pore at 1.07–1.37 (1.20) from anterior end. Vulva located at 10.31–11.29 (10.83) from anterior end. Cloacal aperture at 1.47–2.04 (1.71) from posterior end. Anal aperture at 0.78–0.96 (0.84) from the posterior end.

Taxonomic summary

Infection site: stomach.

Locality: Bella Vista, San Martín, Peru (7°15' S, 76°28' W).

Specimens deposited: MUSM 3252.

Prevalence: 25% (2 infected marsupials of 8).

Mean intensity: 11.5.

Mean abundance: 2.87.

Remarks

Lent and Freitas (1937a) described *Physaloptera mirandai* recovered from the brown four-eyed opossum *M. nudicaudatus* in Brazil. Our specimens show morphometric characteristics similar to those indicated in the original description of *P. mirandai* by Lent and Freitas (1937a). This species has been previously registered in Peru by Tantaleán et al. (2010) in *M. nudicaudatus*. This paper constitutes the first record of *P. mirandai* parasitizing to *D. marsupialis* (Vicente et al., 1997).

Turgida turgida (Rudolphi, 1819) Travassos, 1919

Taxonomic summary

Infection site: stomach.

Locality: Bella Vista, San Martín, Peru (7°15' S, 76°28' W).

Specimens deposited: MUSM 3403.

Prevalence: 13% (1 infected marsupial of 8).

Mean intensity: 2.

Mean abundance: 0.25.

Remarks

Turgida turgida (Rudolphi, 1819) Travassos, 1919, is a common parasite of marsupials from North and South America (Gomes et al., 2003). Adult worms are found parasitizing the stomach, mainly the greater curvature, producing a large fibrous ulceration at the point of attachment (Alden, 1995; Gray & Anderson, 1982; Humberg et al., 2011). The taxo-

nomic characters used by us to identify our specimens follow Matey, Kuperman, and Kinsella (2001) and Travassos (1920). According to Gomes et al. (2003), Humberg et al. (2011), Pinto et al. (2011) and Vicente et al. (1997), *T. turgida* is parasite of *D. albiventris*, *D. aurita*, *D. marsupialis*, *D. virginiana*, *Caluromys philander*, *Ch. minimus*, and *M. nudicaudatus* from Brazil. In Peru, Tantaleán et al. (2010) recorded this species from *P. opossum*.

Family Trichuridae Railliet, 1915

Trichuris marsupialis (Rud, 1819) Hall, 1916

Description: based on 10 adult specimens (5 male and 5 female). *Male:* Body 12.5–15.5 (14.65) long. Spicules 0.90–1.30 (0.97) long. Cloaca at 1.26–1.50 (1.30) from posterior end. *Female:* Body 13.6–20.23 (17.45) long. Eggs 0.062–0.068 (0.066) long by 0.031–0.032 (0.031) wide.

Taxonomic summary

Infection site: stomach.

Locality: Bella Vista, San Martín, Peru (7°15' S, 76°28' W); Lamas, San Martín, Peru (6°25' S, 76°30' W).

Specimens deposited: MUSM 3256.

Prevalence: 50% (4 infected marsupials of 8).

Mean intensity: 12.

Mean abundance: 6.

Remarks

Trichuris marsupialis has been found parasitizing the intestine of *D. virginiana* in the United States of America by Babero (1960); *D. marsupialis*, *Didelphis* sp., *D. virginiana*, and *P. opossum* from Mexico by Acosta-Virgen et al. (2015) and Monet-Mendoza, Osorio-Sarabia, and García-Prieto (2005), and in *D. albiventris* from Brazil by Pinto et al. (2011). In Peru, *Trichuris* sp. has been registered in the intestine of four marsupial hosts (Tantaleán et al., 2010). Thus, *T. marsupialis* represents the first species recorded from marsupials of Peru.

Family Viannaiidae Durette-Desset & Chabaud, 1981

Viannia hamata Travassos, 1914

Description: based on 10 adult specimens (5 male and 5 female). *Male:* Body 2.65–2.82 (2.79) long by 0.130–0.172 (0.154) wide. Cephalic expansion 0.045–0.047 (0.046) long. Esophagus 0.305–0.320 (0.316) long. Excretory pore at 0.312–0.340 (0.320) from anterior end. Spicules 0.133–0.140 (0.138) long. Gubernaculum 0.019–0.023 (0.022) long. *Female:* Body 2.42–3.80 (3.29) long by 0.175–0.220 (0.200) wide. Cephalic expansion 0.040–0.047 (0.046) long. Esophagus 0.250–0.352 (0.322) long. Excretory pore at 0.282–0.354 (0.334) from anterior end. Vulva located at the middle of the body 0.073–0.103 (0.099) from the anterior end. Eggs 0.054–0.062 (0.059) long by 0.04–0.06 (0.05) wide.

Taxonomic summary

Infection site: stomach.

Locality: Bella Vista, San Martín, Peru (7°15' S, 76°28' W); Lamas, San Martín, Peru (6°25' S, 76°30' W).

Specimens deposited: MUSM 3404.

Prevalence: 38% (3 infected marsupials of 8).

Mean intensity: 41.3.

Mean abundance: 15.5.

Remarks

Our specimens show morphometric characteristics similar to those indicated in the redescription of *V. hamata* by Guerrero (1985). *Viannaia hamata* had been recorded only in *D. marsupialis* and *D. aurita* from Brazil (Gomes et al., 2003; Pinto & Gomes, 1980; Pinto et al., 2011); therefore, *Viannaia hamata* represents a new record in Peru.

Viannaia viannaia Travassos, 1914

Description: based on 10 adult specimens (5 male and 5 female). *Male:* Body 1.650–2.720 (2.360) long by 0.077–0.16 (0.106) wide. Cephalic expansion 0.035–0.050 (0.047) long. Esophagus 0.221–0.290 (0.278) long. Excretory pore at 0.270–0.355 (0.320) from anterior end. Spicules 0.097–0.117 (0.108) long. *Female:* Body 2.30–3.13 (3.09) long by 0.140–0.210 (0.180) wide. Cephalic expansion 0.030–0.048 (0.044) long. Esophagus 0.251–0.352 (0.320) long. Excretory pore at 0.284–0.350 (0.330) from anterior end. Vulva located at the middle of the body 0.072–0.102 (0.097) from the anterior end. Eggs 0.052–0.062 (0.057) long by 0.04–0.06 (0.05) wide.

Taxonomic summary

Infection site: stomach.

Locality: Bella Vista, San Martín, Peru (7° 15' S, 76° 28' W).

Specimens deposited: MUSM 3255.

Prevalence: 25% (2 infected marsupials of 8).

Mean intensity: 72.5.

Mean abundance: 18.2.

Remarks

The genus *Viannaia* was erected by Travassos (1914) to accommodate those species of neotropical Trichostrongylidae with short spicules (Guerrero, 1985). Our specimens completely correspond with the original description given by Travassos (1914) and the redescription made by Guerrero (1985) for *Viannaia viannaia*. This nematode was recorded in *D. marsupialis*, *D. aurita*, *P. opossum*, and *Akodon cursor* (Winge, 1887) from Brazil; *D. virginiana* in USA, *D. marsupialis* and *P. opossum* in Venezuela and *D. marsupialis* and *P. opossum* in Mexico (Jiménez et al., 2011; Vicente et al., 1997). This paper constitutes the first record of *V. viannaia* in Peru.

To date, a total of 38 helminth parasites have been recorded in Peruvian marsupials (Table 1), all in adult stage. Digeneans have the highest species richness in number and percentage ($n = 19$, 50%), followed by nematodes ($n = 17$, 45%) and acanthocephalans ($n = 2$, 5%). The parasites with the highest numbers of records were the digeneans *Plagiorchis didelphidis* (Parona, 1896) Stossich, 1904 ($n = 4$) and *Rhopalium coronatus* Kifune & Uyema, 1982 ($n = 4$), and the nematode *Aspidodera* sp. ($n = 4$). For Peru information exists on the parasites of 10 marsupials, distributed in 7 genera: *Chironectes* (1 sp.), *Didelphis* (2 spp.),

Marmosa (1 sp.), *Marmosops* (1 sp.), *Metachirus* (1 sp.), *Monodelphis* (2 spp.) and *Philander* (2 spp.) (Table 2). Marsupials that harbored the highest number of parasites were *D. marsupialis* ($n = 22$) followed by *P. opossum* ($n = 15$), *M. nudicaudatus* ($n = 13$) and *D. albiventris* ($n = 6$) (Table 2). The localities with the highest number of records were Huánuco (28%, $n = 15$), Loreto (21%, $n = 11$) and San Martín (21%, $n = 11$) (Table 1).

Discussion

As a result of this study, we report 11 helminth species (3 digeneans and 9 nematodes) in the helminth communities of *D. marsupialis* from San Martín region, Peru. Species of parasites that represent new records for the country include *V. viannaia*, *V. hamata*, and *G. marsupialis*. All parasites recorded in this study are reported for the first time from the San Martín region.

In the present study, nematodes represented 82% of the total species in the component community of *D. marsupialis*. The composition of the majority of parasite communities of didelphid marsupials show a higher number of nematode species (Acosta-Virgen et al., 2015; Alden, 1995; Grover & Harkema, 1970; Jiménez et al., 2011; Monet-Mendoza et al., 2005). According to Acosta-Virgen et al. (2015), the structuring factor of the helminthofauna in marsupials is the diet; most of the nematode species infect these host species through ingestion of eggs, larvae or intermediate hosts.

In the present work, 6 of 11 helminth species collected in *D. marsupialis* have indirect patterns of transmission by intermediate host ingestion (*G. marsupialis*, *P. didelphidis*, *R. caballeroi*, *R. coronatus*, *P. mirandai*, and *T. turgida*) and 5 are transmitted directly by ingestion of eggs (*A. raillieti*, *C. tentaculata*, *T. marsupialis*, *V. hamata*, and *V. viannaia*). The helminthofauna of *D. marsupialis* in San Martín seemed to be dominated by helminths with direct patterns of transmission. This is indicated by the highest values of prevalence of *A. raillieti*, *C. tentaculata*, and *T. marsupialis*, which exceeded 49%. In contrast, helminths with indirect patterns of transmission had low values of prevalence. Jiménez et al. (2011) mention 2 hypotheses to explain the low prevalence values in helminths with indirect patterns of transmission, including as the main reason the wide spectrum of food items used by marsupials such as *D. marsupialis*.

The checklist presented herein includes 32 named and 6 undetermined species of helminths associated with 10 marsupial host species from Peru; these come from 7 of the 26 Peruvian regions. The greatest richness of parasites was registered among digeneans (19 spp.) and nematodes (17 spp.), in contrast to what was observed by Jiménez, Scheibel, Byles, and Gardner (2013) in the parasites of marsupials in Bolivia, where nematodes and cestodes are the dominant group of parasites, while digeneans barely are represented by 2 species; this situation also was observed by Pérez-Ponce de León, García-Prieto, and Mendoza-Garfias (2007) in digeneans of marsupials from Mexico, where digeneans showed a low species richness. The large number of species being represented by digeneans in this work could be a result of the extraordinary diversification of sites of infection,

Table 1

List of records of helminth species from marsupials in Peru, with their hosts, locality, site and data-sources.

Parasite	Host	Locality	Site	References
Phylum Platyhelminthes Gegenbaur, 1959				
Class Trematoda Rudolphi, 1808				
Family Duboisiiellidae Sudarikov, 1959				
<i>Duboisiiella proloba</i> Baer, 1938	<i>Didelphis marsupialis</i> , <i>Metachirus nudicaudatus</i> , <i>Philander opossum</i>	Huánuco	Caecum, intestine	Miyazaki et al. (1978)
Family Diplostomidae Poirier, 1886				
<i>Bursotrema tetracotyloides</i> Szidat, 1960	<i>Didelphis marsupialis</i> , <i>Philander</i> <i>opossum</i>	Huánuco	Small intestine	Kifune and Uyema (1982)
<i>Fibricola gradosi</i> Kifune & Uyema, 1982	<i>Didelphis marsupialis</i>	Huánuco	Small intestine	Kifune and Uyema (1982)
<i>Fibricola inca</i> Kifune & Uyema, 1982	<i>Didelphis albiventris</i>	Cajamarca	Small intestine	Kifune and Uyema (1982)
<i>Podospathalum pedatum</i> (Diesing, 1850) Dubois, 1932	<i>Monodelphis adusta</i> , <i>Philander</i> <i>opossum</i>	Loreto	Intestine	Tantaleán et al. (2010)
Family Dicrocoeliidae Odhner, 1910				
<i>Opisthobranchylecithum ambiguum</i> Kifune & Uyema, 1982	<i>Metachirus nudicaudatus</i>	Huánuco	Small intestine	Kifune and Uyema (1982)
<i>Zonorchis allentoshi</i> (Foster, 1939) Travassos, 1944	<i>Philander opossum</i>	Loreto	Bile duct	Kifune and Uyema (1982)
Family Plagiorchiidae Ward, 1917				
<i>Plagiorchis didelphidis</i> (Parona, 1896) Stossich, 1904	<i>Didelphis marsupialis</i> , <i>Didelphis</i> <i>albiventris</i> , <i>Metachirus</i> <i>nudicaudatus</i> , <i>Philander</i> <i>opossum</i>	Cajamarca, Huánuco, San Martín	Caecum, small intestine	Miyazaki et al. (1978), Tantaleán et al. (1992), present study
Family Microphallidae Travassos, 1921				
<i>Microphallus garciai</i> Ibáñez, 1973	<i>Didelphis marsupialis</i> , <i>Didelphis</i> <i>albiventris</i>	Cajamarca	Small intestine	Tantaleán et al. (1992)
Family Rhopalidae (Looss, 1899) Viana, 1924				
<i>Rhopalias baculifer</i> Braun, 1900	<i>Didelphis marsupialis</i> , <i>Metachirus nudicaudatus</i> , <i>Philander opossum</i>	Huánuco	Small intestine	Miyazaki et al. (1978), Tantaleán et al. (1992)
<i>Rhopalias caballeroi</i> (Rudolphi, 1819) Stiles & Hassall, 1898	<i>Didelphis marsupialis</i> , <i>Philander</i> <i>opossum</i>	Cuzco, Huánuco, San Martín	Large intestine, small intestine, stomach	Kifune and Uyema (1982), Tantaleán et al. (1992), Tantaleán and Chávez (2004), present study
<i>Rhopalias coronatus</i> Kifune & Uyema, 1982	<i>Didelphis marsupialis</i> , <i>Didelphis</i> <i>albiventris</i> , <i>Metachirus</i> <i>nudicaudatus</i> , <i>Philander</i> <i>opossum</i>	Cajamarca, Huánuco, San Martín	Small intestine	Miyazaki et al. (1978), Tantaleán et al. (1992), present study
<i>Rhopalias horridus</i> (Diesing, 1850) Stiles & Hassall, 1898	<i>Didelphis marsupialis</i> , <i>Philander</i> <i>opossum</i>	Huánuco	Small intestine	Miyazaki et al. (1978)
<i>Rhopalias</i> sp.	<i>Didelphis marsupialis</i>	Cuzco	Large intestine	Tantaleán and Chávez (2004)
Family Opisthorchiidae Braun, 1901				
<i>Amphimerus minutus</i> Artigas & Pérez, 1964	<i>Didelphis marsupialis</i>	Huánuco	Bile duct, gallbladder, pancreatic duct	Kifune and Uyema (1981), Tantaleán et al. (1992)
<i>Amphimerus neotropicales</i> Caballero, Montero Gei & Caballero, 1963	<i>Didelphis albiventris</i>	Huánuco	Bile duct, pancreatic duct	Miyazaki et al. (1978), Tantaleán et al. (1992)
<i>Amphimerus ruparupa</i> Kifune & Uyema, 1981	<i>Philander opossum</i>	Huánuco, Loreto	Bile duct, gallbladder, pancreatic duct, stomach, intestine	Kifune and Uyema (1981), Tantaleán et al. (1992)
Family Paragonimidae Dollfus, 1939				
<i>Paragonimus amazonicus</i> Miyazaki, Grados & Uyema, 1973	<i>Chironectes minimus</i> , <i>Philander</i> <i>opossum</i>	Huánuco	Lungs	Tantaleán et al. (1992)
<i>Paragonimus mexicanus</i> Miyazaki & Ishii, 1968	<i>Didelphis albiventris</i>	Cajamarca	Lungs	Tantaleán et al. (1992)

Table 1 (Continued)

Parasite	Host	Locality	Site	References
Phylum Acanthocephala Rudolphi, 1808 Class Archiacanthocephala Meyer, 1931 Family Gigantorhynchidae Hamann, 1892				
<i>Gigantorhynchus lutzi</i> Machado, 1941	<i>Didelphis marsupialis</i> , <i>Marmosops noctivagus</i> , <i>Metachirus nudicaudatus</i>	Huánuco, Loreto	Small intestine	Tantaleán et al. (2005, 2010)
<i>Gigantorhynchus ortizi</i> Sarmiento, 1953	<i>Metachirus nudicaudatus</i>	Junín	Small intestine	Tantaleán et al. (2005)
Phylum Nematoda Rudolphi, 1808 Family Aspidoderidae Skrjabin & Schikhobalova, 1947				
<i>Aspidodera raillieti</i> Travassos, 1913	<i>Didelphis marsupialis</i>	San Martín, Huánuco	Small intestine	Sarmiento et al. (1999), present study
<i>Aspidodera</i> sp.	<i>Marmosops</i> cf. <i>noctivagus</i> , <i>Metachirus nudicaudatus</i> , <i>Marmosa regina</i> , <i>Philander opossum</i>	Loreto	Large intestine	Tantaleán et al. (2010)
Family Kathlanidae Lane, 1914				
<i>Cruzia americana</i> Maplestone, 1930	<i>Didelphis marsupialis</i>	Lima	Caecum, small intestine	Sarmiento et al. (1999)
<i>Cruzia tentaculata</i> (Rudolphi 1819) Travassos, 1917	<i>Didelphis marsupialis</i> , <i>Metachirus nudicaudatus</i>	Cajamarca, Lima, San Martín	Caecum, small intestine	Sarmiento et al. (1999), Arrojo (2002), Tantaleán et al. (2010), present study
Family Gnathostomatidae Railliet, 1895				
<i>Gnathostoma turgidum</i> Stossich, 1902	<i>Didelphis marsupialis</i> , <i>Metachirus nudicaudatus</i>	Huánuco	Stomach	Miyazaki et al. (1978), Sarmiento et al. (1999)
Family Gongylonematidae Sobolev, 1949				
<i>Gongylonemoides marsupialis</i> (Vaz & Pereira, 1934) Freitas & Lent, 1937	<i>Didelphis marsupialis</i>	San Martín	Trachea	Present study
Family Physalopteridae Railliet, 1893				
<i>Physaloptera mirandai</i> Lent & Freitas 1937	<i>Didelphis marsupialis</i> , <i>Metachirus nudicaudatus</i>	Loreto, San Martín	Stomach	Tantaleán et al. (2010), present study
<i>Physaloptera</i> sp.	<i>Metachirus nudicaudatus</i> , <i>Philander opossum</i>	Loreto	Stomach	Tantaleán et al. (2010)
<i>Turgida turgida</i> (Rudolphi 1819) Travassos, 1920	<i>Didelphis marsupialis</i> , <i>Philander opossum</i>	Loreto, San Martín	Stomach	Tantaleán et al. (2010), present study
Family Trichuridae Railliet, 1915				
<i>Trichuris didelphis</i> Babero, 1960	<i>Didelphis marsupialis</i>	San Martín	Small intestine	Present study
<i>Trichuris</i> sp.	<i>Marmosops</i> cf. <i>noctivagus</i> , <i>Philander andersoni</i> , <i>Philander opossum</i>	Loreto	Large intestine	Tantaleán et al. (2010)
Family Viannaiidae Neveu-Lemaire, 1944				
<i>Viannaia hamata</i> Travassos, 1914	<i>Didelphis marsupialis</i>	San Martín	Small intestine	Present study
<i>Viannaia viannai</i> Travassos, 1914	<i>Didelphis marsupialis</i>	San Martín	Small intestine	Present study
<i>Viannaia</i> sp.	<i>Marmosops noctivagus</i> , <i>Metachirus nudicaudatus</i>	Loreto	Small intestine	Tantaleán et al. (2010)
Family Rictulariidae Railliet, 1916				
<i>Pterygodermatites</i> sp.	<i>Marmosa regina</i>	Loreto	Small intestine	Tantaleán et al. (2010)
Family Onchocercidae				
<i>Litomosoides wilsoni</i> Guerrero, Martin, Gardner, & Bain, 2002	<i>Monodelphis emiliae</i>	Cuzco	Abdominal cavity	Guerrero et al. (2002), Morales et al. (2005)
Family Oxyuridae				
<i>Monodelphoxyuris dollmeiri</i> Guerrero & Hugot, 2003	<i>Monodelphis emiliae</i>	Cuzco	Caecum	Guerrero and Hugot (2003), Morales et al. (2005)

life-cycles, and in the modes of feeding (Pérez-Ponce de León et al., 2007).

The second species-richest taxon was Nematoda, represented by 17 species, similar to compiled by García-Prieto et al. (2012), who listed 14 named and 7 unidentified nematode species in marsupials from Mexico, but it is a different number to that reported from Bolivia (21 nematode species) (Jiménez et al.,

2013). According to Garrido-Olvera, García-Prieto, and Pérez-Ponce de León (2006), nematodes are probably the second largest taxon in the Animal kingdom after arthropods, when considering the number of described and estimated unknown species.

The other group of parasites, Acanthocephala, was represented by only a few species, which corresponds to the situation

Table 2
Host–parasite list of Peruvian marsupials with their helminth species.

Host	Parasite
Order Didelphimorphia (Gill, 1872)	
Family Didelphidae Gray, 1821	
<i>Chironectes minimus</i> (Zimmermann, 1780)	<i>Paragonimus amazonicus</i> (TE)
<i>Didelphis albiventris</i> Lund, 1840	<i>Amphimerus neotropicalis</i> (TE) <i>Fibricola gradosi</i> (TE) <i>Microphallus garciai</i> (TE) <i>Paragonimus mexicanus</i> (TE) <i>Plagiorchis didelphidis</i> (TE) <i>Rhopalias coronatus</i> (TE)
<i>Didelphis marsupialis</i> Linnaeus, 1758	<i>Amphimerus minutes</i> (TE) <i>Bursotrema tetracotyloides</i> (TE) <i>Duboisella prolobo</i> (TE) <i>Fibricola gradosi</i> (TE) <i>Microphallus garciai</i> (TE) <i>Plagiorchis didelphidis</i> (TE) <i>Rhopalias baculifer</i> (TE) <i>Rhopalias caballeroi</i> (TE) <i>Rhopalias coronatus</i> (TE) <i>Rhopalias horridus</i> (TE) <i>Rhopalias</i> sp. (TE) <i>Gigantorhynchus lutzi</i> (AC) <i>Aspidodera raillieti</i> (NE) <i>Cruzia americana</i> (NE) <i>Cruzia tentaculata</i> (NE) <i>Gnathostoma turgidum</i> (NE) <i>Gongylonemoides marsupialis</i> (NE) <i>Physaloptera mirandai</i> (NE) <i>Trichuris didelphis</i> (NE) <i>Turgida turgida</i> (NE) <i>Viannaia hamata</i> (NE) <i>Viannaia viannai</i> (NE)
<i>Marmosa (Micoureus) regina</i> Thomas, 1898	<i>Aspidodera</i> sp. (NE) <i>Pterygodermatites</i> sp. (NE)
<i>Marmosops noctivagus</i> (Tschudi, 1844)	<i>Gigantorhynchus lutzi</i> (AC) <i>Aspidodera</i> sp. (NE) <i>Trichuris</i> sp. (NE) <i>Viannaia</i> sp. (NE)
<i>Metachirus nudicaudatus</i> (É. Geoffroy, 1803)	<i>Duboisella prolobo</i> (TE) <i>Opisthobranchylecithum ambiguum</i> (TE) <i>Plagiorchis didelphidis</i> (TE) <i>Rhopalias baculifer</i> (TE) <i>Rhopalias coronatus</i> (TE) <i>Gigantorhynchus lutzi</i> (AC) <i>Gigantorhynchus ortzi</i> (AC) <i>Aspidodera</i> sp. (NE) <i>Cruzia tentaculata</i> (NE) <i>Gnathostoma turgidum</i> (NE) <i>Physaloptera mirandai</i> (NE) <i>Physaloptera</i> sp. (NE) <i>Viannaia</i> sp. (NE)
<i>Monodelphis adusta</i> (Thomas, 1897)	<i>Podospathalium pedatum</i> (NE)
<i>Monodelphis emiliae</i> (Thomas, 1912)	<i>Litomosoides wilsoni</i> (NE)
<i>Philander andersoni</i> (Osgood, 1913)	<i>Monodelphoxyuris dollmeiri</i> (NE)
<i>Philander opossum</i> (Linnaeus, 1758)	<i>Trichuris</i> sp. (NE) <i>Amphimerus ruparupa</i> (TE)

Table 2 (Continued)

Host	Parasite
	<i>Bursotrema tetracotyloides</i> (TE) <i>Duboisella prolobo</i> (TE) <i>Paragonimus amazonicus</i> (TE) <i>Plagiorchis didelphidis</i> (TE) <i>Podospathalium pedatum</i> (TE) <i>Rhopalias baculifer</i> (TE) <i>Rhopalias caballeroi</i> (TE) <i>Rhopalias coronatus</i> (TE) <i>Rhopalias horridus</i> (TE) <i>Zonorchis allentoshi</i> (TE) <i>Aspidodera</i> sp. (NE) <i>Physaloptera</i> sp. (NE) <i>Trichuris</i> sp. (NE) <i>Turgida turgida</i> (NE)

AC: Acanthocephala, NE: Nematoda, TE: Trematoda.

in Mexico (García-Prieto, García-Varela, Mendoza-Garfias, & Pérez-Ponce de León, 2010).

The digeneans *Amphimerus neotropicales* Caballero, Montero, Gei & Caballero, 1963, *Duboisella prolobo* Baer, 1938, *P. didelphidis*, *Rhopalias baculifer* Braun, 1900, *R. coronatus* and *Rhopalias horridus* (Diesing, 1850) Stiles & Hassall, 1898 and the nematode *Gnathostoma turgidum* Stossich, 1902 were the first species of helminths recorded from Peruvian marsupials (Miyazaki et al., 1978).

In Peru, there are 40 known marsupial species (Pacheco et al., 2009), of which only 25% (10 hosts of one family) have parasitological records; this information likely corresponds to only a small proportion of the true richness of parasites with a high amount of diversity remaining untouched. The marsupial species *D. marsupialis*, *P. opossum*, *M. nudicaudatus*, and *D. albiventris* presented the highest richness of parasites. This is similar to that reported from Mexico, where *D. marsupialis* and *P. opossum* are the hosts with the highest number of helminth parasites after *D. virginiana* (Pérez-Ponce de León & García-Prieto, 2001).

Acknowledgements

To Ney Saavedra Grandez and Pol Martan Huayama Alverca for their invaluable help collecting opossums. Our appreciation is extended to Blanca Saldaña Arevalo and Alex Ruser Vela Noriega for assistance in the parasitological examinations. We are grateful to Eric Wetzel for useful comments on an early draft of the manuscript.

References

- Acosta-Virgen, K., López-Caballero, J., García-Prieto, L., & Mata-López, R. (2015). Helminths of three species of opossums (Mammalia, Didelphidae) from Mexico. *ZooKeys*, 511, 131–152.
- Adnet, F. A. O., Anjos, D. H. S., Menezes-Oliveira, A., & Lanfredi, R. M. (2009). Further description of *Cruzia tentaculata* (Rudolphi, 1819) Travassos, 1917 (Nematoda: Cruzidae) by light and scanning electron microscopy. *Parasitology Research*, 104, 1207–1211.
- Alden, K. J. (1995). Helminths of the opossum, *Didelphis virginiana*, in Southern Illinois, with a compilation of all helminths reported from this host in North America. *Journal of the Helminthological Society of Washington*, 62, 197–208.

- Amin, O. M. (2013). Classification of the Acanthocephala. *Folia Parasitologica*, 60, 273–305.
- Anderson, R., Chabaud, A., & Willmott, S. (2009). *Keys to the nematode parasites of vertebrates* (Archival Volume) London: CAB International.
- Aponte, Q. J. A. (2013). Una revisión de la biología del *Didelphis marsupialis* y su relación con el mal de Chagas y la leishmaniasis. *Hipótesis, Apuntes científicos Uniandinos*, 96, 95–101.
- Arrojo, L. (2002). Parásitos de animales silvestres en cautiverio en Lima, Perú. *Revista Peruana de Biología*, 9, 118–120.
- Babero, B. B. (1960). Further studies on helminthes of the opossum, *Didelphis virginiana*, with a description of a new species from this host. *Journal of Parasitology*, 46, 455–463.
- Bush, A., Lafferty, K., Lotz, J., & Shostak, A. (1997). Parasitology meets ecology on its own terms: Margolis et al. revisited. *Journal of Parasitology*, 83, 575–583.
- Chagas-Moutinho, V. A., Oliveira-Menezes, A., Cárdenas, M. Q., & Lanfredi, R. M. (2007). Further description of *Aspidodera railletii* (Nematoda: Aspidoderidae) from *Didelphis marsupialis* (Mammalia: Didelphidae) by light and scanning electron microscopy. *Parasitology Research*, 101, 1331–1336.
- Emmons, L. H., & Feer, F. (1997). *Neotropical rain forest mammals, a field guide* (2nd ed.). Chicago: The University of Chicago Press.
- Fernandes, B. M. M., Justo, M. C. N., & Cárdenas, M. Q. (2015). *South American trematodes parasites of birds and mammals*. Rio de Janeiro: Biblioteca de Ciências Biomédicas. ICICT. Fiocruz – RJ.
- Freitas, J., & Lent, H. (1937). Notas sobre Gongyloneminae Hall, 1916 (Nematoda: Spiruroidea). *Memorias do Instituto Oswaldo Cruz*, 32, 299–304.
- García-Prieto, L., Falcón-Ordaz, J., & Guzmán-Cornejo, C. (2012). Helminth parasites of wild Mexican mammals: list of species, hosts and geographical distribution. *Zootaxa*, 3290, 1–92.
- García-Prieto, L., García-Varela, M., Mendoza-Garfias, B., & Pérez-Ponce de León, G. (2010). Checklist of the Acanthocephala in wildlife vertebrates of Mexico. *Zootaxa*, 2419, 1–50.
- Garrido-Olvera, L., García-Prieto, L., & Pérez-Ponce de León, G. (2006). Checklist of the adult nematode parasites of fishes in freshwater localities from Mexico. *Zootaxa*, 1201, 1–45.
- Gibson, D. J., Jones, A., & Bray, R. A. (2002). *Keys to the Trematoda* (Vol. 1) London: CAB International and the Natural History Museum.
- Gomes, D. C., da Cruz, R. P., Vicente, J. J., & Pinto, R. M. (2003). Nematode parasites of marsupials and small rodents from the Brazilian Atlantic Forest in the State of Rio de Janeiro, Brazil. *Revista Brasileira de Zoologia*, 20, 699–707.
- Gray, J. B., & Anderson, R. C. (1982). Observations on *Turgida turgida* (Rudolphi, 1819) (Nematoda: Physalopteroidea) in the American opossum (*Didelphis virginiana*). *Journal of Wildlife Diseases*, 18, 279–285.
- Grover, C. M., & Harkema, R. (1970). Helminths of the Opossum (*Didelphis virginiana*) in North Carolina. *The Helminthological Society of Washington*, 37, 36–39.
- Guerrero, R. (1985). Trichostrongyloidea parásitos de mamíferos silvestres de Venezuela. II Revisión del género *Viannia* Travassos, 1914. *Memoria de la Sociedad de Ciencias Naturales La Salle*, 124, 9–47.
- Guerrero, R., & Hugot, J. P. (2003). *Monodelphoxyuris dollmeiri* n. g., n. sp. (Nematoda: Oxyurida) from *Monodelphis emiliae* in Peru. *Systematic Parasitology*, 55, 73–79.
- Guerrero, R., Martin, C., Gardner, S. L., & Bain, O. (2002). New and known species of *Litomosoides* (Nematoda: Filarioidea): important adult and larval characters and taxonomic changes. *Comparative Parasitology*, 69, 177–195.
- Haverkost, T., & Gardner, S. L. (2008). A review of species in the genus *Rhopalias* (Rudolphi, 1819). *Journal of Parasitology*, 94, 716–726.
- Humberg, R. M. P., Tavares, L. E. R., Paiva, F., Oshiro, E. T., Bonamigo, R. A., Júnior, N. T., et al. (2011). *Turgida turgida* (Nematoda: Physalopteroidea) parasitic in white-bellied opossum, *Didelphis albiventris* (Marsupialia: Didelphidae), state of Mato Grosso do Sul, Brazil. *Pesquisa Veterinária Brasileira*, 31, 78–80.
- Jiménez, F. A., Catzeflis, F., & Gardner, S. L. (2011). Structure of parasite component communities of *Didelphis Marsupials*: insights from a comparative study. *Journal of Parasitology*, 97, 779–787.
- Jiménez, F., Scheibel, R., Byles, B., & Gardner, S. (2013). *The metazoan parasites of opossums in Bolivia: an inventory of 25% of marsupial diversity*. ASP Annual Meeting, North America, March, 2013. Retrieved from: <http://parasitology.winston.wfu.edu/asp/index.php/meeting/asp2013/paper/view/377>
- Jiménez-Ruiz, A., Gardner, S. L., & Varela-Stokes, A. S. (2006). Aspidoderidae from North America, with the description of a new species of *Aspidodera* (Nematoda: Heterakoidea). *Journal of Parasitology*, 92, 847–854.
- Kifune, T., & Uyema, N. (1981). Reports of Fukuoka University Scientific Expedition to Peru, 1976. Part 2. Taxonomical studies on two species of the genus *Amphimerus* from opossums with a description of a new species (Trematoda: Opisthorchiidae). *Medical Bulletin of Fukuoka University*, 8, 393–400.
- Kifune, T., & Uyema, N. (1982). Reports of Fukuoka University Scientific Expedition to Peru, 1976. Part 3. Taxonomical studies on trematodes from marsupials and rodents with records of two crabs. *Medical Bulletin of Fukuoka University*, 9, 241–256.
- Lamothe-Argumedo, R. (1997). *Manual de técnicas para preparar y estudiar los parásitos de animales silvestres*. México D.F.: A.G.T. Editor., 43 pp.
- Lent, H., & Freitas, J. (1937a). Nova *Physaloptera* parasite de marsupial (Nematoda: Spiruroidea). *Memorias do Instituto Oswaldo Cruz*, 32, 221–223.
- Lent, H., & Freitas, J. (1937b). Notas sobre Gongyloneminae Hall, 1916 (Nematoda: Spiruroidea). *Memorias do Instituto Oswaldo Cruz*, 32, 299–304.
- Matey, V. E., Kuperman, B. I., & Kinsella, J. M. (2001). Scanning electron microscopy of *Turgida turgida* (Nematoda: Spiruroidea), parasite of the Virginia opossum, *Didelphis virginiana*, from Southern California. *Journal of Parasitology*, 87, 1199–1202.
- Miyazaki, I., Kifune, T., Habe, S., & Uyema, N. (1978). *Reports of Fukuoka University Scientific Expedition to Peru, 1976. Part 1. General account of the Expedition and records of helminth parasites of wild mammals mollusks and insects*. Department of Parasitology, School of Medicine, Fukuoka University Occ. Publ. ii xi, 1–28.
- Monet-Mendoza, A., Osorio-Sarabia, D., & García-Prieto, L. (2005). Helminths of the Virginia opossum *Didelphis virginiana* (Mammalia: Didelphidae) in Mexico. *Journal of Parasitology*, 91, 213–219.
- Morales, E., Sarmiento, L., Sánchez, L., Floríndez, D., & Lamas, G. (2005). Material tipo de helmintos en el Museo de Historia Natural, Universidad Nacional Mayor de San Marcos, (MUSM), Lima, Perú. *Revista Peruana de Biología*, 12, 463–472.
- Pacheco, V., Cadenillas, R., Salas, E., Tello, C., & Zeballos, H. (2009). Diversidad y endemismo de los mamíferos del Perú. *Revista Peruana de Biología*, 16, 5–32.
- Pérez-Ponce de León, G., & García-Prieto, L. (2001). Diversidad de helmintos parásitos de vertebrados silvestres de México. *Biodiversitas*, 6, 7–11.
- Pérez-Ponce de León, G., García-Prieto, L., & Mendoza-Garfias, B. (2007). Trematode parasites (Platyhelminthes) of wildlife vertebrates in Mexico. *Zootaxa*, 1534, 1–247.
- Pinto, R. M., & Gomes, C. D. (1980). Contribuição ao conhecimento da fauna helmintológica da região Amazonica. Nematódeos. *Atas da Sociedade de Biologia do Rio de Janeiro*, 21, 65–79.
- Pinto, R. M., Knoff, M., Gomes, C. D., & Noronha, D. (2011). Nematodes from mammals in Brazil: an updating. *Neotropical Helminthology*, 5, 139–183.
- Rivillas, C., Caro, E., Carvajal, H., & Vélez, I. (2004). Algunos tremátodos digeneos (Rhopaliasidae, Opisthorchiidae) de *Philander opossum* (Marsupialia) de la costa pacífica colombiana, incluyendo *Rhopalias caucensis* n. sp. *Revista de la Academia Colombiana de Ciencias Exactas, Físicas y Naturales*, 28, 591–600.
- Rodrigues, H. O. (1994). *Plagiorchis vicentei*, sp. n. (Trematoda, Plagiorchidae) a new trematode from *Hemidactylus maboula* (Moreau de Jonnes) (Lacertilla, Gekkonidae). *Revista Brasileira de Zoologia*, 11, 669–672.
- Rodríguez-Ortiz, B., García-Prieto, L., & Pérez-Ponce de León, G. (2004). Checklist of the helminth parasites of vertebrates in Costa Rica. *Revista de Biología Tropical*, 52, 313–354.
- Rueda, M. C., Ramírez, G. F., & Osorio, J. H. (2013). Aproximación a la biología de la zarigüeya común (*Didelphis marsupialis*). *Boletín Científico Museo de Historia Natural Centro de Museos, Universidad de Caldas*, 17, 141–153.
- Santos, C., Lent, H., & Gomes, D. C. (1990). The genus *Aspidodera* Railliet and Henry, 1912 (Nematoda: Heterakoidea): revision, new genus and key for species. *Revista Brasileira de Biología*, 50, 1017–1031.

- Sarmiento, L., Tantaleán, M., & Huiza, A. (1999). Nematodos parásitos del hombre y de los animales en el Perú. *Revista Peruana de Parasitología*, *14*, 9–65.
- Tantaleán, M., & Chávez, J. (2004). Wild animal endoparasites (Nemathelminthes and Plathelminthes) from the Manu Biosphere Reserve, Peru. *Revista Peruana de Biología*, *11*, 219–222.
- Tantaleán, M., Díaz, M., Sánchez, N., & Portocarrero, H. (2010). Endoparásitos de micromamíferos del noroeste de Perú I: helmintos de marsupiales. *Revista Peruana de Biología*, *17*, 207–213.
- Tantaleán, M., Sánchez, L., Gómez, L., & Huiza, A. (2005). Acantocéfalos del Perú. *Revista Peruana de Biología*, *12*, 83–92.
- Tantaleán, M., Sarmiento, L., & Huiza, A. (1992). Dígeneos (Trematoda) del Perú. *Boletín de Lima*, *80*, 47–84.
- Travassos, L. (1913). Sobre as espécies brasileiras da subfamília Heterakinae Railliet & Henry, 1912. *Memorias do Instituto Oswaldo Cruz*, *5*, 271–318.
- Travassos, L. (1914). Tricostrongylídeos brasileiros. *Brasil Médico*, *34*, 325–327.
- Travassos, L. (1917). Alguns helmintos da coleção do Instituto Bacteriológico de São Paulo. *Brasil Médico*, *31*, 99–100.
- Travassos, L. (1920). Contribuições para o conhecimento da fauna helmintológica brasileira. X. Sobre as espécies do gênero *Turgida*. *Memórias do Instituto Oswaldo Cruz*, *12*, 73–77.
- Travassos, L. (1922). Contribuição para o conhecimento da fauna helmintológica brasileira. XVI. *Cruzia tentaculata* (Rud. 1819). *Memorias do Instituto Oswaldo Cruz*, *14*, 88–94.
- Vaz, Z., & Pereira, C. (1934). Two new parasitic worms of *Didelphis aurita*: *Skryabinofilaria pricei* n. sp. and *Gongylonema marsupialis* n. sp. *Journal of the Washington Academy of Sciences*, *24*, 54–56.
- Vicente, J. J. (1966). Revisão da subfamília Aspidoderinae Skjabin & Shikhobalova, 1947 (Nematoda). *Memórias do Instituto Oswaldo Cruz*, *64*, 131–161.
- Vicente, J. J., Rodrigues, H. O., Gomes, D. C., & Pinto, R. M. (1997). Nematóides do Brasil. Parte V: Nematóides de mamíferos. *Revista Brasileira de Zootologia*, *Curitiba*, *14*, 1–452.